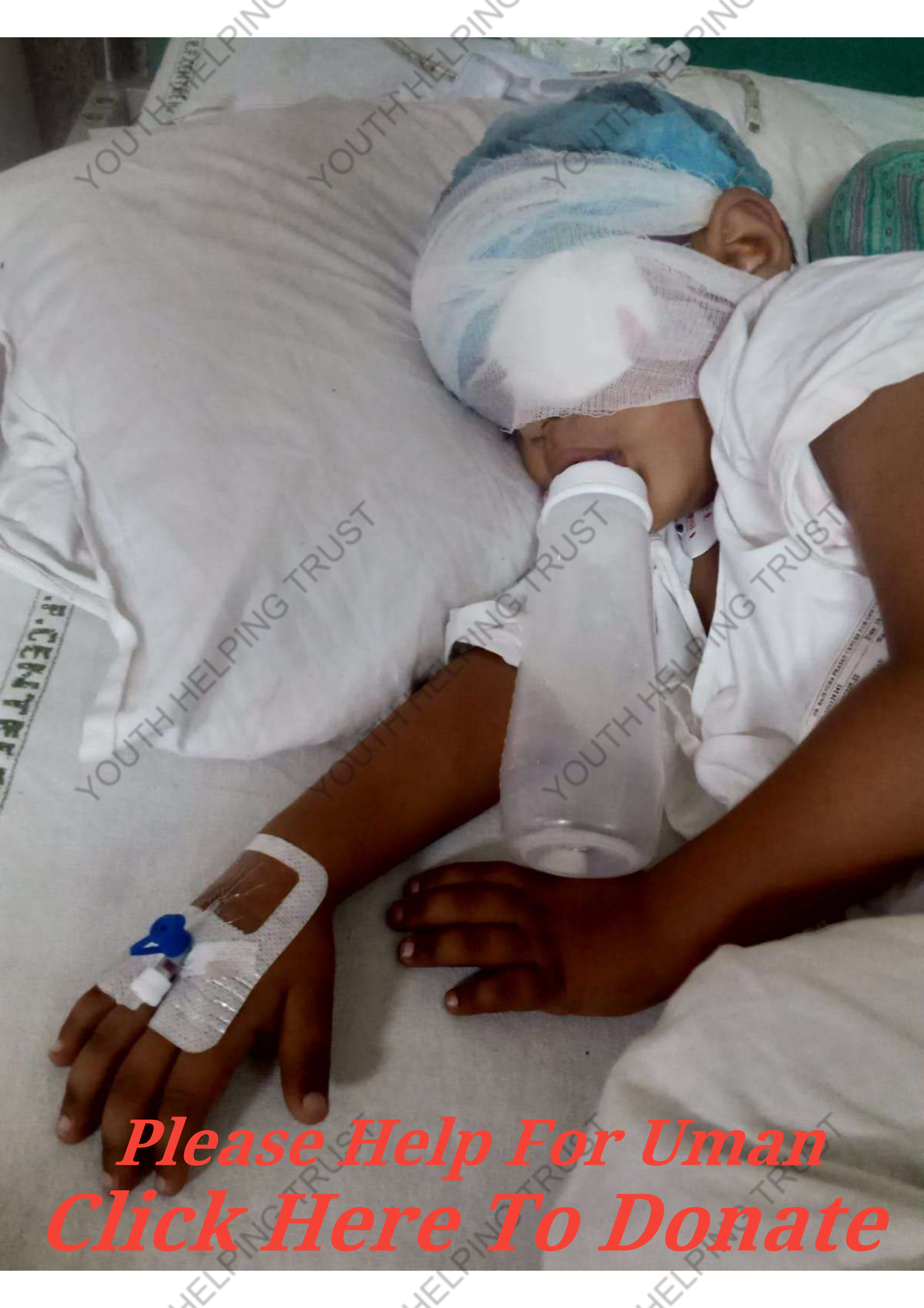
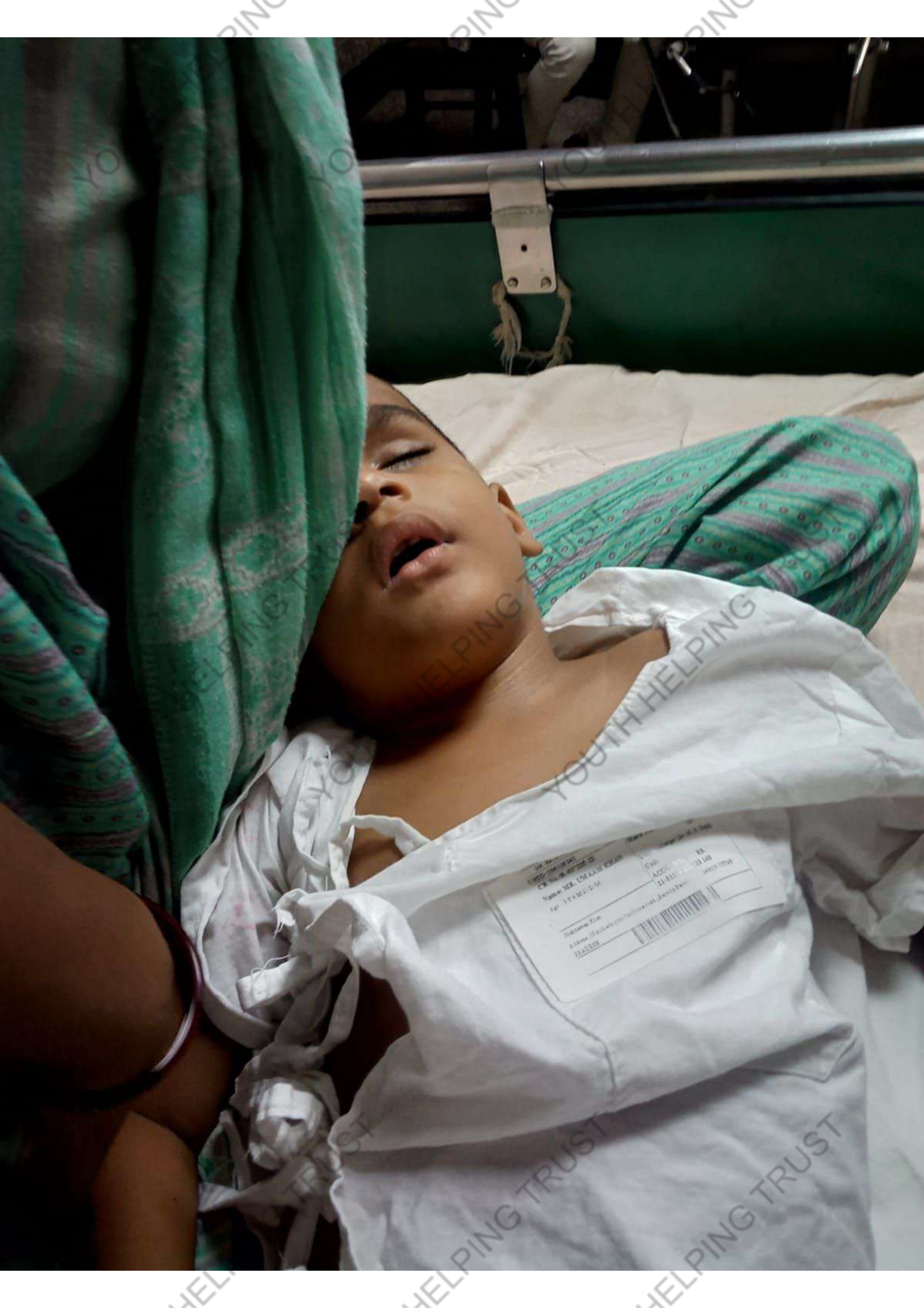


*Please Help For Uman
Click Here To Donate*



MR. UKALAK KRAK	1980-08-28	M	A
Age: 3741010	21-11-10	11 110	1111 1111
Barcode			

CHILD: 106130241
No: 20220050086123
B. P. Centre (T.H. Centre)
RPC OPD-M. SR RPC
UNIT 35 B
No: 35B
DATE: 10/11/2023

ब० रो० वि० कार्ड O.P.D. Card

डा० राजेन्द्र प्रसाद नेत्र विज्ञान केन्द्र
अ० मा० आयु० सं०, नई दिल्ली - 110029
Dr. Rajendra Prasad Centre for Ophthalmic Sciences
A.I.I.M.S., New Delhi-110029



अनुभाग व दिन
Section and Day
सोमवार व बृहस्पतिवार
Monday & Thursday

कमरा नंबर
Cabin No.

यू०एचआईडी संख्या
UHID No. 10 6126241

आचार्य एस. के. खोखर का एकक
Prof. S. K. Khokhar's Unit

रोगी का नाम Name of the Patient	पुत्र/पुत्री/पत्नी S/D/W	लिंग Sex	आयु Age	पता Address
Umam	3y1M	M kgp		

दिनांक DATE	निदान DIAGNOSIS
----------------	--------------------

उपचार Treatment

Δ R/E) WNL L/E) Enucleated for GYFE RB.
FTWBCS (Postdated) / eIAB/
MONICU stay for 1 day d/t jaundice on the 3rd day of birth
No H/O yamoris, seizure, Heart disease, asthma
(K) developmental history
H/O cycles of chemo (VCR, Carboplatin, VP)
last → 24/1/2023.
H/O L/E) enucleation on October 2022 → GA → U/E
H/O EOA & GA on 10/10/22 → GA → U/E
H/O chicken pox from 6/2/2023 on T. Herotko, Crocin syp
syp. aciclovir x 5 days.
No H/O urt | currently
No H/O drug allergy -

16/11/23
HB - 12.4
PLT - 259
TLC - 4700

कृपया इस कार्ड को सुरक्षित रखें तथा अस्पताल में दिखाने के समय हर वक्त साथ लायें।
Kindly keep this Card safely and bring it on your follow-up visits.

- धूम्रपान निषेध 1. No Smoking
- कूड़ा कर्कट केवल कूड़ेदान में ही डालें 2. Use Dustbin
- थूकिये नहीं 3. No Spitting



अखिल भारतीय आयुर्विज्ञान संस्थान, नई दिल्ली 110029
All India Institute of Medical Sciences, New Delhi-110029
परामर्श अभिलेख / CONSULTATION RECORD

नाम Name	Umesh	आयु Age	3 yrs	लिंग Sex	M	वैवाहिक स्थिति Marital Status	गृहस्थ	यु.एच.आई.सी. सं. UID No.	10612624
सेवा Service		वार्ड Ward	Paediatric	बिस्तर Bed		व्यवसाय Occupation		रक्तसम Rhesus	स्थिति Status
Referred by Dr.	Dr. P. K. Das	Requesting Doctor		to Dr.	Dr. S. K. Chakraborty	Consultant & Specialty			
Date :									

Findings :

Case of testis blastoma (extra ocular) &
w/ vomiting / headache
Kindly evaluate for Papilloedema.

Diagnosis or Impression :

[Signature]

विकिरण नैदानिक विभाग
अ० भा० आ० सं०, नई दिल्ली-११००२६
DEPARTMENT OF RADIODIAGNOSIS
A.I.I.M.S., NEW DELHI - 110029

PLAIN X-RAY/CONTRAST STUDIES REQUISITION FORM

Name : Umaam

Age/Sex : 3y/m

Ref. Deptt./Unit : Paediatrics

Date : 11/12/21

Indoor (Bed No.) / Outdoor / Casualty

UHID No. : 106126241 LMP :

Examination Required :

Clinical History and Examination :

Abt X-ray PA view

FN fever

? LATI

Clinical / Working Diagnosis :

Blood Urea / S. Creatinine :
Any h / o allergy or asthma :
(for IVU patients only) :

Signature of Referring Physician / Date :

Consent :

I hereby give consent for the performance of any diagnostic or therapeutic radiological procedure without the use of contrast injection and / or sedation. The associated complications and risks have been explained to me.

Signature of Patient / Date :

Room No. : _____

Your appointment is on : _____

Time Slot : 8:30

9:00

9:30

10:00

10:30

11:00

11:30

X-Ray No. :

Size / No. of Films

Date :

Kvp/mAS:

Sign. of Radiographer :

विकिरण नैदानिक विभाग
अ० भा० आ० सं०, नई दिल्ली-११००२६
DEPARTMENT OF RADIODIAGNOSIS
A.I.I.M.S., NEW DELHI - 110029

PLAIN X-RAY/CONTRAST STUDIES REQUISITION FORM

Name : Umaam

Age/Sex : 3y/m

Ref. Deptt./Unit : Paediatrics

Date : 11/12/21

Indoor (Bed No.) / Outdoor / Casualty

UHID No. : 106126241 LMP :

Examination Required :

Clinical History and Examination :

Abt Xray PA view

FN fever

? LATI

Clinical / Working Diagnosis :

Blood Urea / S. Creatinine :
Any h / o allergy or asthma :
(for IVU patients only) :

Signature of Referring Physician / Date :

Consent :

I hereby give consent for the performance of any diagnostic or therapeutic radiological procedure without the use of contrast injection and / or sedation. The associated complications and risks have been explained to me.

Signature of Patient / Date :

Room No. : _____

Your appointment is on : _____

Time Slot : 8:30

9:00

9:30

10:00

10:30

11:00

11:30

X-Ray No. :

Size / No. of Films

Date :

Kvp/mAS:

Sign. of Radiographer :

PATIENT NAME : UMAAM

UHID : 106126241

AGE : 3Y

SEX : M

REGISTRATION DATE : 26-07-2022

MOBILE NUMBER : 9027097798

ADDRESS : 05 KULHA DA PEER BANKHANA ROAD, BAREILLY, UP

DIAGNOSIS : EORB

RE : WNL

LE : GRPE

CHEMO : 4

1ST CHEMO : 19/09/22

LAST CHEMO : 19/09/22
12/11/2022

ENUCLATION : NA Post chemo

DATE OF SURGERY :
NA 31/10/2022

HPE NO :
NA 22-1262

HPE FINDINGS :
NA MCM

MRI FINDINGS : OPTIC NERVE INV. MIDORBIT (TILL APEX)

STAGE : 3

DATE OF MRI : 02/08/2022

SURGEON : DR. PRITHVI

EBRT :

REMARKS :

EBRT Registration for Extra Ocular
Rb involving optic nerve
Patient has received 2 cycles of chemo.
Kindly see details above

Prithvi



Histopathology Report
Ocular Pathology
Dr. Rajendra Prasad Centre for Ophthalmic Sciences
All India Institute of Medical Sciences
Ansari Nagar, New Delhi - 110029, India

Provisional

Name of the Patient: Umaam Khan

Lab Reference No.: 22-1262

Age: 3 Years Sex: Male

Received on: 31/10/2022

UHID No.: 106126241

Date of Report: 9/11/2022

Ward: IB

Bed No.: 137

Unit Incharge: Prof. Bajaj

Nature of the Material Submitted: Enucleation.

Report:

- Enucleated left eyeball.
- Poorly differentiated retinoblastoma (LTD 10mm).
- Tumour shows necrosis and calcification.
- Tumour is infiltrating the choroid extensively with RPE proliferation.

Optic nerve sections are being examined to rule out invasion.

Moh.

Reported By

Dr. Rajendra Prasad Centre For Ophthalmic Sciences
ALL INDIA INSTITUTE OF MEDICAL SCIENCES (AIIMS), New Delhi - 110029

Discharge Report
OCCUPATION:

UNIT :
Name:
Age/Sex:
Weight Name:
Date of Admission:
Discharge Summary Preparation Date:
Discharge Type :

ID No: 141
Mr. Anshu Khan
3 years 4 months 24 days / Male
18
28/10/2022 12:10:00 PM
01/11/2022 11:13:33 AM
Procedure Done:

CR No:
Department:
Unit:
Bed No.:

R-017725-22
R. T. Centre (Eye Centre)
Unit V
137

RE WNL
LE FOUR STAGE 3A S/P 3 CYCLE NAC

Systemic
NO SI

Ocular
VA
RE AT LEAST 6/60
LE NO PL
10P
RE 16 MM HG
LE B/D, SOFT
AL RE 32
LE USG: DISTORTED GLOBE WITH CYSTIC SPACES - NO E/O CALCIFICATION

Surgeon
DR. PRITHVI
Date
31/10/2022

Surgery
1L ENUCLEATION PLUS SILICONE IMPLANT UNDER GA
RE EGA - WNL
SILICONE IMPLANT 20 MM
ON STUMP 13 MM

Vision
LE NO PL
Anterior Seg.
TARSOGRAPHY INTACT, LID SWELLING PRESENT

10P
Posterior Seg.

Oral
SYP AUGMENTIN 270 (SML) 2.5 ML TDS
SYP PCM (250/5ML) 3ML TDS
SYP DIGENE 5 ML BD
Follow Up
WITH DR. PRITHVI AFTER 1 WEEK IN OPD 43 AT 9 AM TUE 6-11-2022

Topical
1L
E/O REEFRESH TEARS 4T/D
E/O VIGAMOX 0.5 percent TDS
E/O OCCUPOL BD
Position
FOLLOW UP WITH HISTOLOGY REPORTS AFTER 1 WEEK FROM 7TH FLOOR

Signature Of Senior Resident/Consultant

Prepared By: Dr. Arnav Panigrahi

Date & Time

11-11-2022 17:06

Name
 Age
 Sex
 Address
 Date
 Signature

Date of Birth
 Date of Admission
 Date of Discharge
 Date of Follow-up


Patient's Name
 Age
 Sex
 Address

R.P.C
 (06126241)

ARYA PATE VENTURE PHARMACY
 (M) MEDICINE RECEIVED

DR. P. P. C
 31/10/2022

DATE
 TIME
 (11/11/22)



Pre chemo NRC (MRI on 2-8-22)
 Large filling whole globe. ON involved all (thickening)
 Torn away from apex. No lymphadenopathy
 3 chemo cycle

MRI (22-12-22) NRC
 Globe Irregular & small in size cystic spaces (+)
 No ON thickening (+). ON stalk visible.
 Fat stranding (+)? d/t inflammatory response

Only info

Dr. P. P. C
 Dr. P. P. C
 Dr. P. P. C

ब. रो. वि. कार्ड
O.P.D. Card

डा. राजेन्द्र प्रसाद नेत्र विज्ञान केन्द्र
अ. भा. आयु. सं., नई दिल्ली - 110029
Dr. Rajendra Prasad Centre for Ophthalmology
A.I.I.M.S., New Delhi-110029

यू.एच.आई.डी. संख्या
UHID No. 10612624



स्वास्थ्य विभाग
जो आप से है वहाँ है

अनुभाग व दिन
Section and Day
मंगलवार व शुक्रवार
Tuesday & Friday

कमरा नंबर
Cabin No.

Sciences

आचार्य एम. एस. बाज का एकक
Prof. M. S. Bajaj's Unit

रोगी का नाम
Name of the Patient
Umapam

पुत्र/पुत्री/पत्नी
S/D/N

लिंग
Sex

आयु
Age

पता
Address

Male

3yrs 7 months

दिनांक
DATE

निदान
DIAGNOSIS

उपचार
Treatment

20/02/2023

RB - EUA

- EUA done by

Diagnosis : RE

LE

→ WNL
→ Enucleated (for group E)

- Date of Enucleation

HRF +/-

→ 21/10/2022
→ Poorly diff. Tumor & necrosis & calcification
→ massive choroidal extension
→ cut end of eye are positive
→ 7 cycles free of tumor

- No. of Chemo Cycles

- Last Chemo on

- EBRT /IAC/ Intravitreal

- Last EUA

TTT/

→ 7 cycles (27/01/2023)
→ to be given after 10 days of discharge

कृपया इस कार्ड को सुरक्षित रखें तथा अस्पताल में दिखाने के समय हमें वक्त साथ लीजिए।
Kindly keep this Card safely and bring it on your follow-up visits.

1. धूम्रपान निषेध
1. No Smoking

2. कूड़ा कर्कट केवल कूड़ेदान में ही डालें
2. Use Dustbin

3. थूकिये नहीं
3. No Spitting

DISCHARGE SLIP
OF MEDICAL SCIENCES
NEW DELHI
ROTARY CANCER

Umapam

U303- 106126241
Dept. No: 20220050080123
UMAAM KHAN
Shahmama Khan

Date: 21/02/2023
RPC OPD- Dr. SR RPC
UNIT 5 35 II
Unit-V
Room No.: 35B

Address: 05 Achhda peer bankwa road, Bareilly, Bareilly, UTTAR PRADESH
Pin: 241003, INDIA
Mobile: 9627097109



अनुभाग व दिन
Day
क्रवार
Friday

कमरा नंबर
Cabin No.

डॉ. राजेंद्र
अ. भी.
Dr. Rajendra
A.I.I.M.
यू.एच.डी.
UHID

रोगी का नाम
Name of the Patient

पुत्र/पुत्री
S/D/W

Sex

पता
Address

दिनांक
DATE

निदान
DIAGNOSIS

उपचार Treatment

31 JAN 2023

Date for EUA

2-3wks

Pacheco

20/02/2023
OT sm place
8:30am to 11:30am

Adc

Steam
Inhaler

Pacheco

for removal
URI

कृपया इस कार्ड को सुरक्षित रखें तथा अस्पताल में दिखाने के समय हर वक्त साथ लायें।
Kindly keep this Card safely and bring it on your follow-up visits.

1. धूम्रपान निषेध
1. No Smoking

2. कूड़ा कर्कट केवल कूड़ेदान में ही डालें
2. Use Dustbin

3. थूकिये नहीं
3. No Spitting

Umaam Khan

DISCHARGE

Admission For

Admission Name

R. P. Centre (For Centre)
 UHID: 106126241
 Dept. No.: 20220050080123
 Clinic. No.: 22
 UMAAM KHAN
 : Shahdara Khan
 Address: 05 kulkarna peer hardhara road, Dwarka, New Delhi, UTTAR PRADESH
 Pin: 243003, INDIA
 Mobile: 9017007708

Date: 19/01/2023
 Retinoblastoma Dr. SR/AR
 RETINOBLASTOMA
 UNDER UNIT V R.142
 Unit V THU
 Room No.: 142 B

अनुभाग व दिन
 Section and Day
 मंगलवार व बुधवार
 Tuesday & Friday

कमरा नंबर
 Cabin No.

UHID No. 106126241

Prof. M. S. Bajaj's Unit

रोगी का नाम Name of the Patient	पुत्र/पुत्री/पत्नी S/D/W	लिंग Sex	आयु Age	पता Address
Umaam Khan		M	3.7 Y	

दिनांक DATE	निदान DIAGNOSIS	उपचार Treatment
19/01/23	RE-WNL / IC-GrPE (ENB) - 31/10/22	

Father → fundus / glow cont, CSR = 0.4:1, AVR = 2:3
 NRE healthy, FR cont, no peripheral Rx lesion.

Mother → fundus / glow cont, CSR = 0.5:1, AVR = 2:3,
 NRE healthy, FR cont, no peripheral Rx lesion.

glow cont, CSR = 0.4:1,
 AVR = 2:3, NRE healthy,
 no peripheral Rx lesion.

कृपया इस कार्ड को सुरक्षित रखें तथा अस्पताल में दिखाने के समय हर वक्त साथ लायें।
 Kindly keep this Card safely and bring it on your follow-up visits.

1. धूम्रपान निषेध
2. कूड़ा कर्कट केवल कूड़ेदान में ही डालें
3. थूकिये नहीं
1. No Smoking
2. Use Dustbin
3. No Spitting

ब० रो० वि० कार्ड
O.P.D. Card

डा० राजेन्द्र प्रसाद नेत्र विज्ञान केंद्र
अ० भा० आयु० से०, नई दिल्ली - 110029
Dr. Rajendra Prasad Centre for Ophthalmic Sciences
A.I.I.M.S., New Delhi-110029

यू०एच०आई०डी० संख्या

UHID No. 106126241

दृष्टि

जिस अंगुली का प्रयोग है
के ज्ञान से व फल है

अनुभाग व दिन
Section and Day
मंगलवार व शुक्रवार
Tuesday & Friday

V

कमरा नंबर
Cabin No.

आचार्य एम. एस. बाजज का एकक
Prof. M. S. Bajaj's Unit

रोगी का नाम
Name of the Patient

पुत्र/पुत्री/पत्नी
S/D/W

लिंग
Sex

आयु
Age

पता
Address

Umar Khom

दिनांक
DATE

निदान
DIAGNOSIS

(LC) Extracocular RB & ON thickening till apex.
उपचार Treatment

10/11/22

Enucleation done on 31/10/22
HPT → Massive choroidal exlusion
Cut end of ON → to be commented.

No of chemos - 4 cycles.

No of GBRT -

- Patient awaiting Radiotherapy for tomorrow

कृपया इस कार्ड को सुरक्षित रखें तथा अस्पताल में दिखाने के समय हर वक्त साथ लायें।
Kindly keep this Card safely and bring it on your follow-up visits.

1. धूम्रपान निषेध 1. No Smoking
2. कूड़ा कर्कट केवल कूड़ेदान में ही डालें 2. Use Dustbin
3. थूकिये नहीं 3. No Spitting

दिनांक - Date

उपचार - Treatment

(21) (2) USG for PSE →
(kindly provide plo)

enlarged globe c
bonne vit US c

? RD

multiple opacities of cornea

? (Rb)

(photo given)

(correlate clinically)

(14) Body weight → 10kg.
(24/7/20)

(16) Grp E Rb c aseptic arthritis
cellulitis

(Ornamental syms)

Oral steroids
x 5 days

Adv

5mg/kg body wt

5ml OD 4hr

Amoxicillin Duo
Symp

10mg/kg

100mg BD

Syp Digne 3ml BD x 7 days

(2-5 ml BD)

c/d what

Plan CE
MRI
after
injection
of cellulitis

228 100/5ml नेत्र ईश्वरीय सर्वश्रेष्ठ उपहार है जिनका मनुष्य जीवन में दान करना परमश्रेष्ठ है।
इनकी पूर्ण रक्षा कीजिए ताकि ये आपकी रक्षा कर सकें।
Eyes are God's most precious gift to man kind and eye donation is the most noble deed.
Take full care of them so that they can take care of you.

Dr. R.P. Centre for Ophthalmic Sciences
New Delhi-29

Flu after 1 wk

Dr. R.P. Centre for Ophthalmic Sciences
New Delhi-29

दिनांक - Date

उपचार - Treatment

20/02/23

05.5 - 9.00 AM Dose

Today's EUA

— (RF) WNL

(IC) emulsified.

Socket
healthy.

Adv.

1. eld mycin (3) H₂O (RF)

2. Flv after 3 cycles of chemotherapy

+ EIBRT → after 4 months

नेत्र ईश्वरीय सर्वश्रेष्ठ उपहार है जिनका मनुष्य जीवन में दान करना परमश्रेष्ठ है।
इनकी पूर्ण रक्षा कीजिए ताकि ये आपकी रक्षा कर सकें।

Eyes are God's most precious gift to man kind and eye donation is the most noble deed.
Take full care of them so that they can take care of you.

Issue Date: 02/04/2022



भारत सरकार

Government of India



उमाम खान

Umaam Khan

जन्म तिथि/DOB: 07/06/2019

पुरुष/ MALE

यह आधार 5 वर्ष की उम्र तक ही वैध है

8168 5745 1022

VID : 9100 8413 7272 6667

मेरा आधार, मेरी पहचान

बाल आधार



भारत सरकार

Government of India



शाहनवाज़ खां

Shahnawaz Khan

जन्म तिथि/DOB: 01/01/1983

पुरुष/ MALE

3569 9332 3192

VID : 9110 5643 7693 5245

मेरा आधार, मेरी पहचान