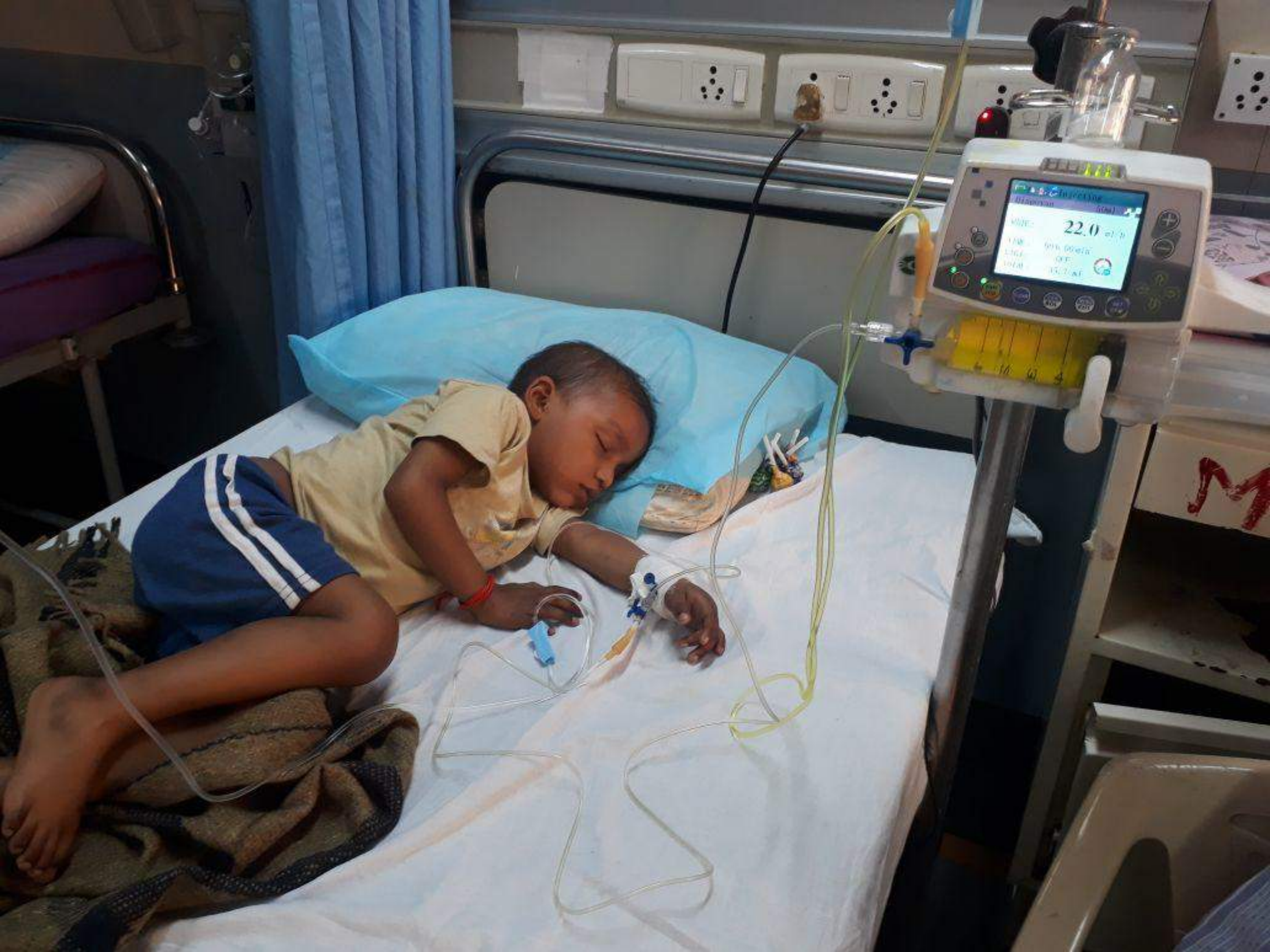
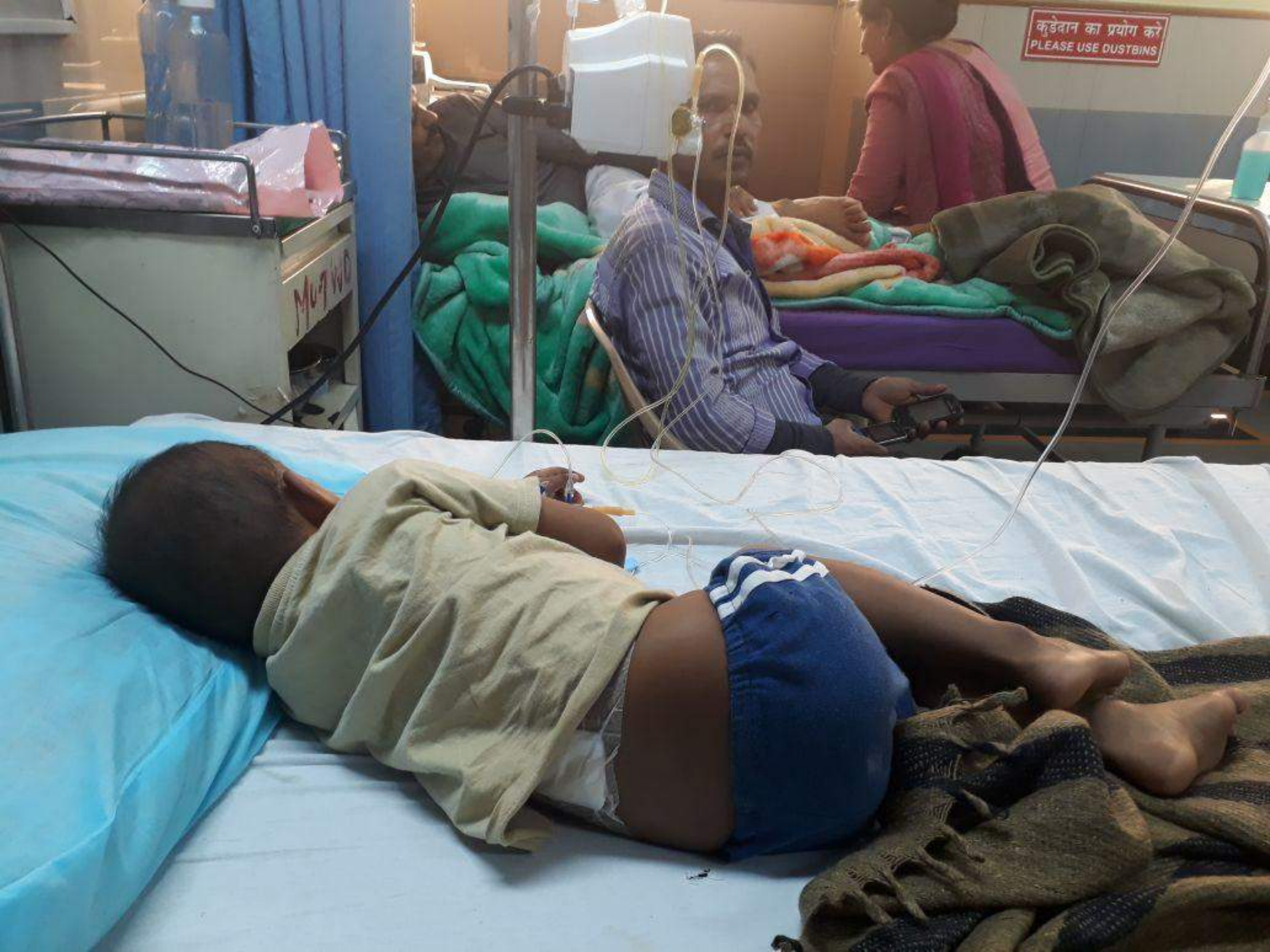


22.0 bpm

Parameter	Value
HR	22.0 bpm
SpO2	95%
ETCO2	35.0 mmHg
FiO2	21.0%









डा. बी. आर. अम्बेडकर संस्थान रोटरी कैंसर अस्पताल  
Dr. B.R. Ambedkar Institute Rotary Cancer Hospital

अ

ITAL

OPR-6

एक/Unit

विभाग/Dept.

नाम/Name

Dept. MEDICAL ONCOLOGY

General

Name RUSTAM KUMAR

S/O- GIRESH KUMAR

Phone No. 8958623774

Address 29 RASULAPUR PO- GHAGHAR, MOHAMMADIAPUR,  
B. AHORI, FIROZABAD, UTTAR PRADESH, Pin: 205141, INDIA

Reg. Date: 09/08/2017

Clinic No. 19709/2017



UHID-103067070

Regn. No.

DOB 11/08/2014 (M/F)

Room 13 (Shift Afternoon)

जन तिथि/Date of Birth

निदान/Diagnosis

B-ALL

MR

दिनांक/Date

1) consolidation उपचार/Treatment

11/12/17

Adv.

T: folinic 5 mg OD x 5 d.

20 PRAC Tz

Continue septran.

my G-CSF 150 mcg qd OD x 3 day

fu on 13/12/17 CBC

from

13.12.17

11-8 > 1450 < 2.0 Lave  
250

Inj. G-CSF 75 mcg SQ OD

2ml FOLINTE 5mg OD

5 day

अंगदान-जीवन का बहुमूल्य उपहार/ORGAN DONATION - A GIFT OF LIFE

O.R.B.O., AIIMS, 26588360, 26593444, www.orbo.org Helpline - 1060 (24 hrs service)

बाहर से आने वाले रोगियों के लिए धर्मशाला की सुविधा उपलब्ध है/Dharamshala facility is available for outstation patients

fever precautions + fu on 18/12 with CBC

LFT+KFT

18/12/17

706.  
Nodori.

Admit for 1st HDMTX

< Sign on 01-01-2018 with CBC+LFT+KFT

27/11/17

3pm

01/12/17 (2)

01/12/17





डा. बी. आर. अ  
Dr. B.R. Ambedkar  
अ.भा.आ.स

Address: 29 RASULAPUR PO- GHAGHAR, MOHARMAADPUR,  
FIROZABAD, UTTAR PRADESH, Pin: 205141, INDIA  
Phone No. 8958623724  
Name: RUSTAM KUMAR  
Specialty: Medical Oncology  
Regd. No. 203444  
Date of Birth: 11/08/2014  
Sex: Male  
Age: 35  
Room No. 13 (Shift Afternoon)  
UHID-103067070

ल  
al

OPR-6

Regd. No. 203444

Dept. MEDICAL ONCOLOGY  
General

Name RUSTAM KUMAR

Sp. GIRISH KUMAR

Phone No. 8958623724

Address: 29 RASULAPUR PO- GHAGHAR, MOHARMAADPUR,  
FIROZABAD, UTTAR PRADESH, Pin: 205141, INDIA

निदान/Diagnosis

दिनांक/Date	उपचार/Treatment
13/11/17	C - d #29
13/11/17	T 6-MP <del>1/2</del> 1/2
13/11/17	Inj. Endoxan 1UP
13/11/17	d1 - 300mg
13/11/17	d2 - 300mg
13/11/17	Inj. Zofen 4mg 1UP
13/11/17	Inj. ARA-C 1UP/50
13/11/17	45/11, 16/11, 17/11, 18/11, 22/11, 23/11, 24/11, 25/11
13/11/17	T. Zofen 4mg orally per ARA-C

अंगदान-जीवन का बहुमूल्य उपहार/ORGAN DONATION - A GIFT OF LIFE

O.R.B.O., AIIMS, 26588360, 26593444, www.orbo.org Helpline - 1060 (24 hrs service)

बाहर से आने वाले रोगियों के लिए धर्मशाला की सुविधा उपलब्ध है/Dharamshala facility is available for outstation patients



DR. B.R.A. IRCHAHMS, NEW DELHI

UHID: 103067070

IRCH No. 203444

Name RUSTAM KUMAR

S/O- GIREESH KUMAR

Phone No. 8958623724

Address 29 RASULAPUR PO- GHAGHAW, MOHAMMADPUR,  
BATHORI, FEROZABAD, UTTAR PRADESH, Pin 203141, INDIA



General

Sex/Age M/3Y

DDSC

Ram Nols

doe 15/11/12

75 mg slc

0.5 x 3 days

on 29/11/12

*Sanjeev Babbar*

01  
27/11

02  
28/11

03  
29/11

30/11/12

29.11.2017

C-day 43

Inj. VCR 0.9 mg IVP. on 29/11 + 6/12

Inj. Pionase 6000 units deep IM on 30/11 + 4/12

7/12 + 9/12

Septoran - M/W/F

Sys. loz 10ml HS QD

In on 11/12/2017 with CBC reports

3rd Avail 0.5 cc Before leucine



डा. बी. आर. अम्बेडकर संस्थान रोटरी कैंसर अस्पताल  
Dr. B.R. Ambedkar Institute Rotary Cancer Hospital  
अ.भा.आ.सं. अस्पताल / A.I.I.M.S. HOSPITAL  
बहिरंग रोगी विभाग / Out Patient Department  
अस्पताल के अन्दर धूम्रपान मना है / SMOKING PROHIBITED IN HOSPITAL PREMISES

OPR-6

203444

DR. B.R.A. IHC/HAHMS, NEW DELHI

CH No. 203444

Clinic: Paed. Lymphoma/Leukemia Clinic

PH. MEDICAL ONCOLOGY

General

Name: RUSTAM KUMAR

DOB: GIRISH KUMAR

Phone No. 8958623724

Address: 29 RASULPUR PO- GHAGHA, MOHAMMADPUR, BAHARU,  
FEROZABAD, UTTAR PRADESH Pin-205141, INDIA

Reg. Date: 06/09/2017

Clinic No. 1971020



UHID-10,000,790

Sex/Age: M

Room: 13 (Shift: Afternoon)

हॉस्पिटल पंजीकृत सं./O.P.D. Regn. No.

श्री/श्री	लिंग Sex	आयु Age	जन्म तिथि/Date of Birth
	M	3	

ALL on consolidation

दिनांक/Date

उपचार/Treatment

3.11.17

fever 101°F today

on 24/10/17 [ 7.9 > 3770 < 82000  
2500 ]

wt => 13 kgs

Adh. [ CBC urgent (outside)  
Blood Cx → Atash them  
Syr. Magnex 1.5 gm iv BID x 4 days  
Syr. T-minic 1 tsf QID  
Syr. Grillin etc 1 tsf QID  
Syr. Crocin (125mg/5ml) 5ml SOS  
Syr. Ondansetron (4mg/5ml) 2.5 ml TDS (premeab)  
M + Lenax  
D4 6/11/17 E

5/61/A  
वातमान  
डॉ. अ. अ. अ.  
90/15/100  
1/6

from 4/11/2017 CBC  
8:30

continue Septan - M/W/F

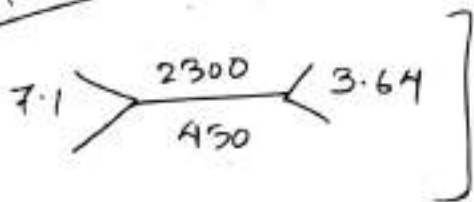
B

अंगदान-जीवन का बहुमूल्य उपहार/ORGAN DONATION - A GIFT OF LIFE

O.R.B.O., AIIMS, 26588360, 26593444, www.orbo.org Helpline - 1060 (24 hrs service)

बाहर से आने वाले रोगियों के लिए धर्मशाला की सुविधा उपलब्ध है/Dharamshala facility is available for outstation patients

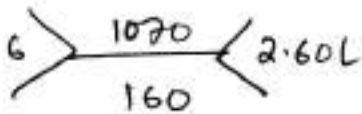
3/11/17



continue antibiotics as written overleaf

R

8.11.17



Adh:

[ Day. GUSF 65 mg 2x OD  
 2nd. Foliate 5mg PO OD ] From No-15  
 5 days  
 BT → 10 PRBC 2nd flow day leave  
 21/8/11  
 132/9/11  
 23/10/11  
 24/11/11  
 13/11 CBC

PRBC  
9/11/17

Syn. Grinlinetun  
2 tof BD

Ⓢ

Ⓢ





डा. बी. आर. अम्बेडकर संस्थान रोटरी कैंसर अस्पताल  
Dr. B.R. Ambedkar Institute Rotary Cancer Hospital  
अ.भा.आ.सं. अस्पताल / A.I.I.M.S. HOSPITAL  
बहिरंग रोगी विभाग / Out Patient Department  
SMOKING PROHIBITED IN HOSPITAL PREMISES

OPR-6

Dept. Reg. No. 203444

Reg. Date-09/08/2017

Clinic No. 19709/2017

ब०रो०वि० पंजीकृत सं०/O.P.D. Regn. No.

Deptt. MEDICAL ONCOLOGY  
General

Name RUSTAM KUMAR

S/O- GIREESH KUMAR

Phone No. 8958623724

Address 29 RASULAPUR PO- GHAGHIAV, MOHAMMADPUR,  
RAHORI, FIROZABAD, UTTAR PRADESH, Pin: 203141, INDIA



UHID-103067070

DOB 11/08/2014 (M/3Y)

Room 13 (Shift Afternoon)

लि/पुत्री ID of	लिंग Sex	आयु Age	जन्म तिथि/Date of Birth

दिनांक/Date

उपचार/Treatment

9/10/17

1. T-6-MP 1 Tab / 1/2 Tab q 4h x 2 wks

2. Inj. ENDOXAN IVP  
d1 - 300mg  
d2 - 300mg

Room No 13

D1CT 9/10/17

D2CT + 2T max 10/10/17

3. Inj. Zofen 4mg IVP d1 d2

4. Inj. ARA-C IVP/SA 45mg  
11/x, 12/x, 13/x, 14/x  
18/x, 19/x, 20/x, 21/x

5. T. Zofen 4mg orally post ARA-C

अंगदान-जीवन का बहुमूल्य उपहार/ORGAN DONATION - A GIFT OF LIFE

O.R.B.O., AIIMS, 26588360, 26593444, www.orbo.org Helpline - 1060 (24 hrs service)

बाहर-से आने वाले रोगियों के लिए धर्मशाला की सुविधा उपलब्ध है/Dharamshala facility is available for outstation patients

Run No-15 1T-MTX 12mg <sup>na dose - 17/10/17</sup> weekly x 2 <sup>हफ्ते में 2</sup>  
 7. Sep. Septeran 1tp <sup>27/10/17</sup> <sup>done on 10/11/17</sup> <sup>done</sup>  
 8. Fu with CBC on 25/10/17

Sunveer

25/10/17

C-day 15  
 Inj. VCR 0.9mg IVP on 26/10 <sup>27/10</sup>  
 Inj. Bionase 6000 units deep IM  
 कागज नं- 15 on 27/10  
 30/10  
 3/11  
 6/11 + Antibiotics

Fu on 8/11/2017 CBC  
 Continue Septeran m/w/F  
 Inj 100 ± 10ml H<sub>2</sub>O  
 रात की सोने  
 को पढ़ने  
 को ब्रशिंग



YUSUF SARAI

Hon. Brig. Dr. Arvind Lal  
M.B.B.S., D.C.P.  
Fellow, F.R.C.P.  
Fellow, F.I.C.P.  
Fellow, F.I.M.S.



CAP  
ACCREDITED



Dr. Vandana Lal  
M.D. (Pathology), F.I.C.P.  
Fellow, F.I.M.S.  
Fellow, F.R.C.P.

Name	: Rustam	Collected:	14-08-2017
Lab No.	: 131469894	Age	: 4 Years
		Gender:	Male
A/C Status	:	Ref by	: Dr. Sameer Bakshi
		Reported:	22-08-2017
		Report status:	Final

## Fluorescence in-situ Hybridization (FISH)

### ALL FISH Panel

Specimen	: Peripheral blood
Clinical Indication	: ? ALL
Result	: nuc ish(BCR×3)(ABL×2)[46/200] : nuc ish(5'MLL,3'MLL)×2(5'MLLcon 3'MLL×2)[200] : nuc ish(TCF3×2)(PBX1×2)[200] : nuc ish(ETV6×2),(RUNX1×4)[72/200]
Interpretation	: Specimen is negative for t(9;22)(q34;q11.2)(BCR/ABL), 11q23(MLL gene rearrangement), t(1;19)(q23;p13.3)(PBX1/TCF3) & t(12;21)(p13;q22)(ETV6)(TEL)/RUNX1(AML1). However one extra green signal for BCR gene in 23% cells & two extra orange signal for RUNX1(21q22) in 36% cells were observed

Probe: ZytoLight SPEC BCR/ABL1 Dual Color Dual Fusion Probe.

Interphase nuclei analyzed	Normal nuclei 2 Orange 2 Green signals	Abnormal nuclei 2 Orange 3 Green signals
200	154	46

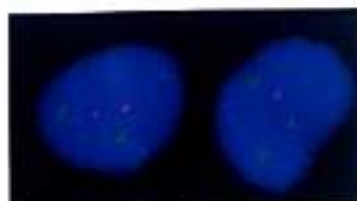
Cut off for the normal individual is 4%

Probe: LSI MLL Dual color, Break Apart Rearrangement probe.

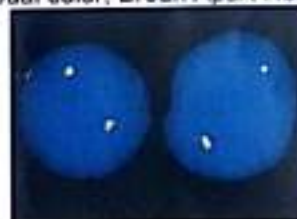Interphase nuclei analyzed	Normal nuclei 2 Yellow	Abnormal nuclei 1 Orange 1 Green 1 yellow signals
200	200	00

Cut off for the normal individual is 3%

BCR/ABL1 Dual Color Dual Fusion



LSI MLL Dual color, Break Apart Rearrangement



Name	: Rustam	Collected:	14-08-2017
Lab No.	: 131469894	Age	: 4 Years
		Gender:	Male
A/C Status	:	Ref by	: Dr. Sameer Bakshi
		Report status:	Final

**Probe:** LSI PBX1 (1q23) S. Orange/LSI TCF3 (19p13.3) S. Green, Vysis, Abbott Molecular Inc.

Interphase nuclei analyzed	Normal nuclei 2 Orange 2 Green signals	Abnormal nuclei 1 Orange 1 Green 2 Yellow signals
200	200	00

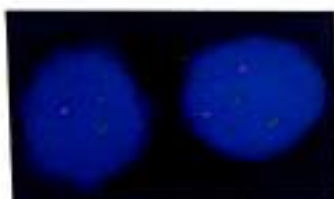
Cut off for the normal individual is 3%

**Probe:** Vysis LSI TEL(ETV6)(12p13) S. Green / LSI RUNX1(21q22) S. Orange Vysis, Abbott Molecular Inc.

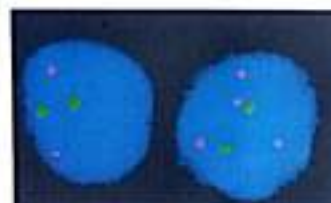
Interphase nuclei analyzed	Normal nuclei 2 Orange 2 Green signals	Abnormal nuclei 4 Orange 2 Green signals
200	128	72

Cut off for the normal individual is 3%

LSI PBX1 (1q23)/ TCF3 (19p13.3)



LSI TEL ETV6(12p13)/ LSI RUNX1(21q22)



**Comment:** t(9;22)(q34;q11.2) is the hallmark of almost all cases of Chronic Myeloid Leukemia (CML). In 5 to 10% of CML patients, the BCR/ABL gene fusion occurs in the absence of a cytogenetically detectable Ph chromosome as a result of more complex rearrangements. It is also seen in 25-30% cases of adult ALL and 2-5% of childhood ALL and is associated with an adverse outcome. Translocations involving the mixed-lineage leukemia (MLL) gene located at chromosomal band 11q23 occur in acute lymphocytic leukemia (ALL). t(1;19), found in 25% of childhood B-ALL with cytoplasmic  $\mu$  expression, fuses the transcription factor produced by TCF3 at 19p13.3 with PBX1 at 1q23. The t(12;21)(p13;q22) chromosomal translocation is the most common chromosomal rearrangement in childhood acute lymphoblastic leukaemia resulting in the fusion of the 5' section of the ETV6(TEL) gene on chromosome 12p13 to almost the entire RUNX1 (AML1) gene on chromosome 21q22. This translocation is present in approximately 30% of childhood pre-B-ALL and 3-4% of adult ALL. t(12;21) cannot be detected by standard cytogenetics unless a more complex rearrangement is present.

**Dr. Saurabh Kumar Bhattacharya**  
Ph. D. Cytogenetics  
HOD

*Leena*  
**Dr. Leena Rawal**  
Ph. D. Molecular Genetics  
Scientist, Cytogenetics



<b>Name:</b>	<b>Rustam</b>	<b>Reg.Date:</b>	<b>15.08.2017</b>	<b>Age/Sex</b>	<b>4 Years M</b>
<b>Lab No:</b>	<b>131469894</b>	<b>Rec.Date:</b>	<b>16.08.2017</b>	<b>Ref.By:</b>	<b>Dr. Sameer Bakshi</b>
<b>Rep Cen:</b>	<b>Yusuf Sarai</b>			<b>Rep.Date:</b>	<b>22.08.2017</b>
<b>Coll.Date:</b>	<b>14.08.2017</b>				

## REPORT OF CHROMOSOME ANALYSIS FOR HEMATOLOGICAL MALIGNANCY

<b>SPECIMEN</b>	:	Peripheral blood
<b>INDICATION</b>	:	? ALL
<b>MEDIUM USED</b>	:	RPMI - 1640, Hi-Karyol RPMI
<b>METHOD</b>	:	24-hr unstimulated cultures with appropriate serum and antibiotics.
<b>BANDING RESOLUTION</b>	:	450-550
<b>BANDING TECHNIQUE</b>	:	GTG (G bands by Trypsin and Giemsa)

### CYTOGENETIC PROFILE:

Metaphases counted	:	20
Metaphases analysed	:	20
Metaphases karyotyped	:	02
Metaphases photographed	:	02

**KARYOTYPE** : 55,XY,+Y,+3,+4,+8,+17,+18,+21,+21,+22[4]/46,XY[16]

### **INTERPRETATION**

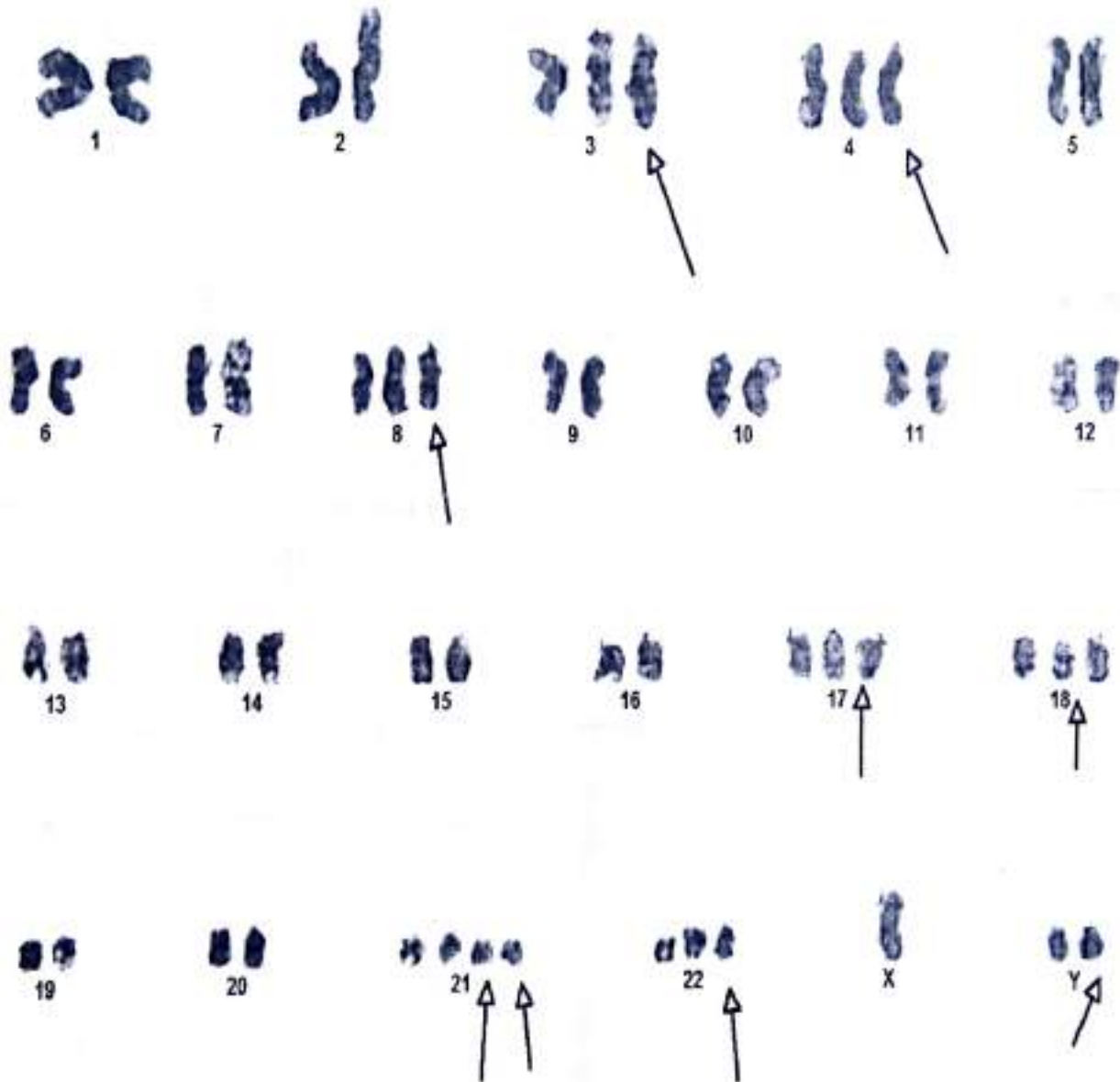
Four of the 20 metaphases analysed are abnormal and show high hyperdiploidy (chromosome number 55) with gains of several chromosomes as listed above including trisomy 4 and tetrasomy 21. High hyperdiploidy is considered as a good prognosis in ALL. Kindly correlate these results with clinical and hematological findings.

### **KARYOGRAM ATTACHED**

*Amal*  
(Hon'ble) Brig. Dr. Arvind Lal  
M.B.B.S., D.C.P.  
Pathology  
FISH/GENETICS PATHOLOGY TO THE RESIDENT OF KDA

*Vandana Lal*  
Dr. Vandana Lal  
M.D. (Pathology), FRCG  
Chief of Pathology  
BANDHANA KANAK DEVI

Name:	Rustam	Age/Sex:	4 Years	M
Lab No:	131469894	Reg.Date:	15.08.2017	
Rep Cen:	Yusuf Sarai	Ref.By:	Dr. Sameer Bakshi	
Coll.Date:	14.08.2017	Rec.Date:	16.08.2017	Rep.Date: 22.08.2017







अखिल भारतीय आयुर्विज्ञान संस्थान, नई दिल्ली-110029  
ALL INDIA INSTITUTE OF MEDICAL SCIENCES, NEW DELHI -110029

आपातकालीन विभाग

(DEPT. OF EMERGENCY MEDICINE)



UHID No:103067070

आपातकालीन नं. (Emergency No): 2017/030/0107694

दिनांक DATE: 13/09/2017

समय TIME: 01:02:19 AM

NON-MLC

नाम NAME: MR. RUSTAM KUMAR

आयु AGE: 3 years 1 months 2 days

लिंग/SEX: M

S/O: GIREESH KUMAR

पता ADDRESS: मकान संख्या H.NO: 29 RASULAPUR PO-GHAGHAV

गली / मुहल्ला STREET/MOH: MOHAMMADPUR, BAHORI

शहर/प्रखंड CITY/BLOCK: FIROZABAD

पिन PIN: 205141

राज्य STATE: UTTAR PRADESH

दूरभाष सं. PHONE NO:

मोबाइल MOBILE NO: 8958623724

स्थान Location: Paediatrics Emergency

द्वारा BROUGHT BY: Relative: FATHER

Criticality: Red / Yellow / Green

Triage: Responsive/ Unresponsive HR /min BP mmHg RR /min SpO2 %

Shifted to Paeds/ Main/ New Emergency

Presenting Complaints

M.O. P/O B-cell ALL (confirmed)  
at Medical Oncology

40 pain abdomen x few hours  
w/o fever / vomiting

Primary Assessment (ABCDE): Assessment Pentagon

Has received Asparaginase  
y'day

<b>Airway</b> Open & stable <u>Yes</u> No If No..... <b>Breathing:</b> RR <u>24</u> /min Efforts: <u>Normal</u> Poor/increased <b>Auscultation:</b> Air entry: <u>Normal</u> poor/Differential Added sounds: <u>None</u> Stridor/Wheeze/Crackles SpO2 on Room air: <u>98%</u>	<b>Circulation</b> <b>108</b> HR...../min CFT.....secs. BP.....mmHg Peripheral pulse: Poor/ <u>Good</u> Central pulse: Poor/ <u>Good</u> Skin temp: <u>Warm</u> cool Others <b>Abdo - soft BS ⊕</b> <b>child</b> <b>uncooperative</b> <b>for exam.</b>	<b>Disability</b> GCS..... <u>15</u> ..... Pupil size..... <u>4</u> .....mm Pupillary Reactions..... <u>4</u> ..... <b>Motor activity:</b> <u>Normal &amp;</u> Symmetrical/Asymmetrical/ Posturing/Flaccidity/Seizure Blood Sugar.....mg/dl Exposure: Temp..... <u>afebrile</u> Colour: <u>Normal</u> pallor/cyanosis /mottled Any other skin lesions.....
---	--	---

Diagnosis

12/9/17

TLC - 1840

12 kg

Hb - 7.0

HwC - 20%

368 (Haptoglobin)

11 - 130

US abdomen

Amylase - (37) SU

Asparaginase

✓ 1st Dose 15mg IV stat

2nd Dose 15mg IV stat

• To monitor serum

ALL INDIA INSTITUTE OF MEDICAL SCIENCES (AIIMS)

New Delhi,  
REQUISITION SLIP



Requested By : Dr.ARUN GARG IRCH

Patient Status : Indoor (IRCH MRO WARD)

Payment Category : General( 0 )

Requisition No: OBR/2017/1741258

Requisition Date : 19/09/2017 01:12 PM

Department Name: Medical Oncology/Unit-I

Unit In-charge : Dr. Lalit Kumar (HOD)

Patient Name:	Mr. RUSTAM KUMAR	Sex: Male
UHD:	103067070	Age: 3 years 1 month 8 days
Address:	Street : 29 RASULAPUR PO- GHAGHAV, MOHAMMADPUR, BAHORI, City : FIROZABAD , State : UTTAR PRADESH, Country : INDIA, Pin : 205141	

Recommended by : Dr. Lalit Kumar (HOD)

Investigation to be done:-

Investigation Category	Investigation Name
X-RAY (IRCH)	CHEST

एल आर वी वार्ड/M.R.O. WARD  
डॉ. वी. आर. ए/DR. B.R.A.  
सर्वसाधारण वार्ड जनरल/IR.C.H.  
दूसरी मंजिल/2nd FLOOR

*[Signature]*

MRO-12

Log 1 = 1  
2/1  
19/9/22



-----  
MEDICAL RECORDProgress Notes  
-----

NOTE DATED: 09/19/2017 15:45

LOCAL TITLE: MED ONCO IRCH DISCHARGE SUMMARY

STANDARD TITLE: DISCHARGE SUMMARY

VISIT: 09/19/2017 15:45 DR OFFICE

Dr BR AMBEDKAR INSTITUTE ROTARY CANCER HOSPITAL, AIIMS, NEW DELHI-110029  
DEPARTMENT OF MEDICAL ONCOLOGY

## DISCHARGE SUMMARY

"UNLESS OTHERWISE SPECIFIED ALL DATES MENTIONED IN THIS NOTE ARE IN THE FORMAT  
MM/DD/YYYY"

## REGISTRATION DETAILS

\*\*\*\*\*

UHID No:103-06-7070

IRCH No:

CR No:

NAME:RUSTAM,RUSTAM

AGE:3

GENDER:MALE

DOA:Sep 14, 2017

DOD:Sep 19, 2017

DURATION OF STAY:6 days

WARD: MRO Ward

BED No:12

CONSULTANT INCHARGE:Dr Sameer Bakshi

ADDRESS:

## DIAGNOSIS &amp; REASON FOR CURRENT ADMISSION

\*\*\*\*\*

CASE SUMMARY: B-ALL

TLC-38180

ON ICICLE PROTOCOL WEF 16/8/17

ON D26 WITH ACUTE ABDOMEN ? VCR INDUCED

ADMITTED FOR :SUPPORTIVE CARE

CASE SUMMARY:RUSTAM 3 YEAR OLD BOY PRESENTED WITH COMPLAINTS OF ON-OFF FEVER OF 1 MONTH DURATION ALONG WITH MULTIPLE NECK AND GROIN SWELLINGS.HE WAS EVALUATED IN OUTSIDE HOSPITAL FOR THE SAME AND WAS FOUND TO HAVE ACUTE LEUKEMIA AND WAS REFERRED TO AIIMS FOR FURTHER EVALUATION AND MANAGEMENT.FLOW CYTOMETRY WAS S/O B-ALL.PATIENT WAS STARTED ON ICICLE PROTOCOL WEF 16/8/17.PATIENT PRESENTED WITH C/O PAIN ABDOMEN, VOMITING,CONSTIPATION.USG Abdomen & Pelvis S/O INTUSUSCEPTION JEJUNOEJUNAL-LEFT QUADRANT.AXR S/O DILATED LOOPS NO E/O OBSTRUCTION.PATIENT WAS TAKEN FOR INTRAOP LAPOROSCOPIC REDUCTION ON 16/9/17 BUT COULD NOT FOUND INTUSUSCEPTION.PATIENT WAS MANAGED CONSERVATIVELY IV FLUIDS/NPO/IV ANTIBIOTICS.PATIENTV IMPROVEED SYMPTOMATICALLY AND IS NOW BEING DISCHARGED IN A MEDICALLY STABLE CONDITION WITH ADVISE TO FOLLOW UP IN OPD

## PRESENTATION AT CURRENT ADMISSION

\*\*\*\*\*

## VITAL SIGNS:

TEMP:98F RESP:18/min PULSE:86/min

BP:106/74mm of Hg SPO2:%

## GENERAL PHYSICAL EXAMINATION: PERFORMANCE STATUS:

PALLOR:- ICTERUS:- OEDEMA:- CYANOSIS:-

STERNAL TENDERNESS:- CLUBBING:- GUM HYPERTROPHY:-

LYMPHNODES:Normal

SPECIFIC FINDINGS:P/A -MILD TENDERNESS, BS+

\*\* THIS NOTE CONTINUED ON NEXT PAGE \*\*

RUSTAM,RUSTAM

103-06-7070 DOB:08/11/2014

AIIMS NEW DELHI

Pt Loc: OUTPATIENT

Printed:09/19/2017 16:03

Vice SF 509

MEDICAL RECORD

Progress Notes

09/19/2017 15:45 \*\* CONTINUED FROM PREVIOUS PAGE \*\*

INVESTIGATIONS AT CURRENT ADMISSION

\*\*\*\*\*

HEMOGRAM:

-----

Hb-----7.5g/dl  
PLATELETS--2.14/microL  
TLC-----1800/microL  
ANC-----/microL  
MCV-----/fL  
PT-----secs  
ESR-----mm/Hr

RADIOLOGY:

USG Abdomen & Pelvis  
INTUSSEPTION JEJUNOEJUNAL-LEFT QUADRANT

STATUS ON DISCHARGE

\*\*\*\*\*

GC at discharge :Fair  
VITAL SIGNS:  
TEMP: 98F RR:18/min PR:86/min BP:102/64mm of Hg  
INVESTIGATIONS:  
Hb:g/dl PLATELETS:/microL TLC:/microL ANC:/microL

ADVICE ON DISCHARGE

\*\*\*\*\*

MEET DIETITIAN IN ROOM NO -153 (FIRST FLOOR IRCH) BEFORE GOING HOME  
Tab Ondansetrone 4mg sos before food  
Tab Pantaprazole 40 mg once a day before food  
Tab Crocin 250MG tab sos for pain/fever  
Hexidine Mouthwash / Steam Inhalation / Sitz Bath thrice a day  
Rest as written in OPD card  
In case of fever/diarrhoea/emergency contact 9868398310

FOLLOW UP

\*\*\*\*\*

Come for follow up in in Board Room on Sep 25,2017 @09:00 with Biochemistry Report, Hemogram Report .

Signed by: /es/ gundu DRNARESH  
09/19/2017 16:03

RUSTAM, RUSTAM  
103-06-7070 DOB:08/11/2014

AIIMS NEW DELHI  
Pt Loc: OUTPATIENT

Printed:09/19/2017 16:03  
Vice SF 509



डा. बी.आर.ए. संस्थान रोटरी कैंसर अस्पताल  
 Dr. B.R.A. INSTITUTE ROTARY CANCER HOSPITAL  
 अखिल भारतीय आयुर्विज्ञान संस्थान, नई दिल्ली-११००२९  
 ALL INDIA INSTITUTE OF MEDICAL SCIENCES, New Delhi-110029  
 छुट्टी का सारांश संक्षेप में  
 DISCHARGE SUMMARY

सी.आर.सं./C.R. No.

O.P.D.O.

Date of Admission/Discharge

नाम/Name

उम्र/Age

लिंग/Sex

History and condition on admission

Hospital Course, Treatment given  
and Condition discharge

PRBC-31120  
 O+ve

Relevant Investigation with Dates

DIAGNOSIS :

ADVICE :

To attend.....Follow up Clinic/O.P.D. on.....

Registrar

MEDICAL RECORD

Progress Notes

NOTE DATED: 08/17/2017 14:04

LOCAL TITLE: MED ONCO IRCH DISCHARGE SUMMARY

STANDARD TITLE: DISCHARGE SUMMARY

VISIT: 08/17/2017 14:04 DR OFFICE

Dr BR AMBEDKAR INSTITUTE ROTARY CANCER HOSPITAL, AIIMS, NEW DELHI-110029  
DEPARTMENT OF MEDICAL ONCOLOGY

DISCHARGE SUMMARY

"UNLESS OTHERWISE SPECIFIED ALL DATES MENTIONED IN THIS NOTE ARE IN THE FORMAT MM/DD/YYYY"

REGISTRATION DETAILS

\*\*\*\*\*

UHID No:103-06-7070 IRCH No: CR No:  
NAME:RUSTAM,RUSTAM AGE:3 GENDER:MALE  
DOA:Aug 16, 2017 DOD:Aug 17, 2017 DURATION OF STAY:1 days  
WARD: MRO Ward BED No:13  
CONSULTANT INCHARGE:Dr Sameer Bakshi  
ADDRESS:

DIAGNOSIS & REASON FOR CURRENT ADMISSION

\*\*\*\*\*

DIAGNOSIS: B-ALL  
TLC-38180  
STEROID PREPHASE W.E.F 16.8.2017

ADMITTED FOR :Evaluation and management

CASE SUMMARY:RUSTAM 3 YEAR OLD BOY PRESENTED WITH COMPLAINTS OF ON-OFF FEVER OF 1 MONTH DURATION ALONG WITH MULTIPLE NECK AND GROIN SWELLINGS.HE WAS EVALUATED IN OUTSIDE HOSPITAL FOR THE SAME AND WAS FOUND TO HAVE ACUTE LEUKEMIA AND WAS REFERRED TO AIIMS FOR FURTHER EVALUATION AND MANAGEMENT.

FLOW CYTOMETRY WAS S/O B-ALL.AFTER SENDING SAMPLES FOR CYTOGENETICS AND ALL PANEL HE WAS STARTED ON STEROID(PREDNISOLONE AT 60 MG/M2) W.E.F 16.8.2017.ALONG WITH STEROIDS HE WAS ALSO GIVEN 1.5 MG OF RASBURICASE AND HYDRATION.HE WAS ALSO TRANSFUSED 1 UNIT PRBC AND 2 UNITS OF PLATELETS .HE IS AFEBILE AND IS NOW BEING DISCHARGED IN A MEDICALLY STABLE CONDITION WITH ADVISE TO FOLLOW UP IN OPD PRESENTATION AT CURRENT ADMISSION

\*\*\*\*\*

VITAL SIGNS:

TEMP:98.6F RESP:22/min PULSE:110/min  
BP:106/72mm of Hg SPO2:99%

GENERAL PHYSICAL EXAMINATION: PERFORMANCE STATUS: ECOG 1

PALLOR:+ ICTERUS:- OEDEMA:- CYANOSIS:-  
STERNAL TENDERNESS:- CLUBBING:- GUM HYPERTROPHY:-  
LYMPHNODES:Enlarged Cervical, Axillary, Inguinal

SPECIFIC FINDINGS:LIVER PALPABLE 7 CMS AND SPLEEN IS PALPABLE 6 CMS BELOW RESPECTIVE COSTAL MARGINS

BIOMETRIC DETAILS: WEIGHT:13kgs HEIGHT:93cms BSA:0.6 m2  
CHEMOTHERAPY

\*\* THIS NOTE CONTINUED ON NEXT PAGE \*\*

RUSTAM,RUSTAM  
103-06-7070 DOB:08/11/2014

AIIMS NEW DELHI  
Pt Loc: OUTPATIENT

Printed:08/17/2017 14:27  
Vice SF 509



MEDICAL RECORD

Progress Notes

08/17/2017 14:04

\*\* CONTINUED FROM PREVIOUS PAGE \*\*

\*\*\*\*\*

AMPUTATION CORRECTION : Not required,  
PROTOCOL: PREDNISOLONE 35 MG W.E.F 16.8.2017  
PROPHYLAXIS: Voriconazole

TRANSFUSIONS

\*\*\*\*\*

PRBCs(no of units): 1  
PRPs(no of units) : 2  
FFP(no of units) : 2

STATUS ON DISCHARGE

\*\*\*\*\*

GC at discharge :Improved

VITAL SIGNS:

TEMP: 98.6F RR:22/min PR:98/min BP:108/77mm of Hg

INVESTIGATIONS:

Hb:8.0g/dl PLATELETS:22000/microL TLC:24900/microL ANC:/microL

ADVICE ON DISCHARGE

\*\*\*\*\*

MEET DIETITIAN IN ROOM NO -153 (FIRST FLOOR IRCH) BEFORE GOING HOME

Hexidine Mouthwash / Steam Inhalation / Sitz Bath thrice a day

Rest as written in OPD card

In case of fever/diarrhoea/emergency contact 9868398310

FOLLOW UP

\*\*\*\*\*

Come for follow up in PAED LL CLINIC in Board Room on Aug 21,2017 with .

Signed by: /es/ SUKESH NAIR  
SENIOR RESIDENT  
08/17/2017 14:27

RUSTAM, RUSTAM  
103-06-7070 DOB:08/11/2014

AIIMS NEW DELHI  
Pt Loc: OUTPATIENT

Printed:08/17/2017 14:27  
Vice SF 509

MEDICAL RECORD

Progress Notes

NOTE DATED: 08/17/2017 14:04

LOCAL TITLE: MED ONCO IRCH DISCHARGE SUMMARY

STANDARD TITLE: DISCHARGE SUMMARY

VISIT: 08/17/2017 14:04 DR OFFICE

Dr BR AMBEDKAR INSTITUTE ROTARY CANCER HOSPITAL, AIIMS, NEW DELHI-110029  
DEPARTMENT OF MEDICAL ONCOLOGY

DISCHARGE SUMMARY

"UNLESS OTHERWISE SPECIFIED ALL DATES MENTIONED IN THIS NOTE ARE IN THE FORMAT MM/DD/YYYY"

REGISTRATION DETAILS

\*\*\*\*\*

UHID No:103-06-7070

IRCH No: CR No:

NAME:RUSTAM,RUSTAM

AGE:3

GENDER:MALE

DOA:Aug 16, 2017

DOD:Aug 17, 2017

DURATION OF STAY:1 days

WARD: MRO Ward

BED No:13

CONSULTANT INCHARGE:Dr Sameer Bakshi

ADDRESS:

DIAGNOSIS & REASON FOR CURRENT ADMISSION

\*\*\*\*\*

DIAGNOSIS: B-ALL

TLC-38180

STEROID PREPHASE W.E.F 16.8.2017

ADMITTED FOR :Evaluation and management

CASE SUMMARY:RUSTAM 3 YEAR OLD BOY PRESENTED WITH COMPLAINTS OF ON-OFF FEVER OF 1 MONTH DURATION ALONG WITH MULTIPLE NECK AND GROIN SWELLINGS.HE WAS EVALUATED IN OUTSIDE HOSPITAL FOR THE SAME AND WAS FOUND TO HAVE ACUTE LEUKEMIA AND WAS REFERRED TO AIIMS FOR FURTHER EVALUATION AND MANAGEMENT.

FLOW CYTOMETRY WAS S/O B-ALL.AFTER SENDING SAMPLES FOR CYTOGENETICS AND ALL PANEL HE WAS STARTED ON STEROID(PREDNISOLONE AT 60 MG/M2) W.E.F 16.8.2017.ALONG WITH STEROIDS HE WAS ALSO GIVEN 1.5 MG OF RASBURICASE AND HYDRATION.HE WAS ALSO TRANSFUSED 1 UNIT PRBC AND 2 UNITS OF PLATELETS .HE IS AFEBILE AND IS NOW BEING DISCHARGED IN A MEDICALLY STABLE CONDITION WITH ADVISE TO FOLLOW UP IN OPD PRESENTATION AT CURRENT ADMISSION

\*\*\*\*\*

VITAL SIGNS:

TEMP:98.6F RESP:22/min PULSE:110/min

BP:106/72mm of Hg SPO2:99%

GENERAL PHYSICAL EXAMINATION: PERFORMANCE STATUS: ECOG 1

PALLOR:+ ICTERUS:- OEDEMA:- CYANOSIS:-

STERNAL TENDERNESS:- CLUBBING:- GUM HYPERTROPHY:-

LYMPHNODES:Enlarged Cervical, Axillary, Inguinal

SPECIFIC FINDINGS:LIVER PALPABLE 7 CMS AND SPLEEN IS PALPABLE 6 CMS BELOW RESPECTIVE COSTAL MARGINS

BIOMETRIC DETAILS: WEIGHT:13kgS HEIGHT:93cms BSA:0.6 m2  
CHEMOTHERAPY

\*\* THIS NOTE CONTINUED ON NEXT PAGE \*\*

RUSTAM,RUSTAM

AIIMS NEW DELHI

Printed:08/17/2017 14:27

103-06-7070 DOB:08/11/2014

Pt Loc: OUTPATIENT

Vice SF 509



MEDICAL RECORD

Progress Notes

08/17/2017 14:04

\*\* CONTINUED FROM PREVIOUS PAGE \*\*

\*\*\*\*\*

AMPUTATION CORRECTION : Not required,  
PROTOCOL: PREDNISOLONE 35 MG W.E.F 16.8.2017  
PROPHYLAXIS: Voriconazole

TRANSFUSIONS

\*\*\*\*\*

PRBCs(no of units): 1  
PRPs(no of units) : 2  
FFP(no of units) : 2

STATUS ON DISCHARGE

\*\*\*\*\*

GC at discharge :Improved

VITAL SIGNS:

TEMP: 98.6F RR:22/min PR:98/min BP:108/77mm of Hg

INVESTIGATIONS:

Hb:8.0g/dl PLATELETS:22000/microL TLC:24900/microL ANC:/microL

ADVICE ON DISCHARGE

\*\*\*\*\*

MEET DIETITIAN IN ROOM NO -153 (FIRST FLOOR IRCH) BEFORE GOING HOME

Hexidine Mouthwash / Steam Inhalation / Sitz Bath thrice a day

Rest as written in OPD card

In case of fever/diarrhoea/emergency contact 9868398310

FOLLOW UP

\*\*\*\*\*

Come for follow up in PAED LL CLINIC in Board Room on Aug 21,2017 with .

Signed by: /es/ SUKESH NAIR  
SENIOR RESIDENT  
08/17/2017 14:27

RUSTAM, RUSTAM  
103-06-7070 DOB:08/11/2014

AIIMS NEW DELHI  
Pt Loc: OUTPATIENT

Printed:08/17/2017 14:27  
Vice SF 509

अखिल भारतीय आयुर्विज्ञान संस्थान, नई दिल्ली-110029  
ALL INDIA INSTITUTE OF MEDICAL SCIENCES, NEW DELHI-110029

नाम Name Rustan Kumar उम्र Age 30 सर्विस Service MD दिनांक Date 16/9/17 यू.एच.आई.डी. नं. UHID No. 103067070  
प्रोफेसर इंचार्ज Professor I/C Notes written by.....

CLINICAL NOTES

16/9/17

Klelo B-cell ALL <sup>82/ma</sup> on Induction w-e-f 16/9/17  
Patient was a symptomatic 3 day. Last vcr - 7/9/17  
Last bgr - 9/9/17

cl - • Reduce passing of stool  
• Pain abdomen & distension } 2 day

Passed ~~feces~~ stool in morning 5-6 am since then not pass stool & flatus.

↓  
Pain & Abdomen & distension 9.00 am

No fever, mucositis, bleeding, oral ulcers.

7.5 > 1800 <  $214 \times 10^3$

USG Abdomen → Small bowel intussusception  
↓ bh  
Repeat USG Persistent Intussusception



3825  
Sundar (109)  
Nul  
Hindalman

PHYSICAL EXAMINATION

Temp.	Pulse	Resp	B.P.	Weight
-------	-------	------	------	--------

O/E

General Condition - fair

Pulse - 102/min  
Bp - 94/6 mmHg.  
SpO<sub>2</sub> - 96% Room air

PIA → Tenderness (+).  
Tympanic on percussion  
Absent Bowel sound.

Resp - B/L chest clear.

Imp → B. pressure ALL on Induction & small  
bowel Intussusception.

Advice → NPO, RT drainage

→ ~~NS~~ DNS 2 (1/10 Kcl) 35ml TRS

→ Advice Admission for Surgical Intervention  
I/O for Intussusception

→ Peds Surgery Rm to review

→ No bed in rect / cmo to help.

  
Jelma



अखिल भारतीय आयुर्विज्ञान संस्थान, नई दिल्ली-110029  
ALL INDIA INSTITUTE OF MEDICAL SCIENCES, NEW DELHI -110029  
आपातकालीन विभाग

(REVISIT)

37



(DEPT. OF EMERGENCY MEDICINE)

UHID No:103067070

आपातकालीन नं. (Emergency No): 2017/030/0107694

दिनांक DATE: 13/09/2017

समय TIME: 01:02:19 AM

NON-MLC

नाम NAME: MR. RUSTAM KUMAR

आयु AGE: 3 years 1 months 2 days

लिंग/SEX: M

S/O: GIREESH KUMAR

पता ADDRESS: मकान संख्या H.NO: 29 RASULAPUR PO- GHAGHAV

गली / मुहल्ला STREET/MOH: MOHAMMADPUR, BAIHORI

शहर/ब्लॉक CITY/BLOCK: FIROZABAD

पिन PIN: 205141

राज्य STATE: UTTAR PRADESH

दूरभाष सं. PHONE NO:

मोबाइल MOBILE NO: 8958623724

स्थान Location: Paediatrics Emergency

द्वारा BROUGHT BY: Relative: FATHER

Criticality: Red / Yellow / Green

Triage: Responsive/ Unresponsive HR /min BP mmHg RR /min SpO2 %

Shifted to Paeds/ Main/ New Emergency

Mo K10 B-cell ALL (confirmed)  
at Medical Oncology

Presenting Complaints

40 pain abdomen x few hours  
no vom / vomiting

Primary Assessment (ABCDE): Assessment Pentagon

was assessed Asparaginase  
y'day

<b>Airway</b> Open & stable: <u>Yes</u> /No If No..... <b>Breathing:</b> RR <u>24</u> /min Efforts: <u>Normal</u> /Poor/increased <b>Auscultation:</b> Air entry: <u>Normal</u> /poor/Differential Added sounds: <u>None</u> /Stridor/Wheeze/Crackles SpO2 on Room air: <u>98%</u>	<b>Circulation</b> to & HR...../min CFT.....secs. BP.....mmHg Peripheral pulse: Poor/ <u>Good</u> Central pulse: Poor/ <u>Good</u> Skin temp: <u>Warm</u> /cool Others <u>Abdo - soft BS+</u> <u>child</u> <u>uncooperative</u> <u>for exam.</u>	<b>Disability</b> GCS..... <u>15</u> ..... Pupil size: <u>4</u> mm Pupillary Reactions: <u>4</u> ..... <b>Motor activity:</b> <u>Normal &amp;</u> <u>Symmetrical</u> /Asymmetrical/ Posturing/Flaccidity/Seizure Blood Sugar.....mg/dl Exposure: Temp..... <u>afebrile</u> Colour: <u>Normal</u> /pallor/cyanosis /mottled Any other skin lesions.....
--	--	---

Diagnosis

12/9/17

TLc - 1840

12 kg

Wb - 7.0

Hb - 20.1

368 (w/fev)

11 - 13 (1)

US abdomen

Amylase - (37) SU

Adm

✓ Pancreas 15mm IV stat

✓ Vessel 15mm IV stat

• Toxicology screen



7. ~~St. Ly~~ ~~European~~ 5 mg in ~~st~~  
Tab Lantol 3R (15 mg) 1 tab 10 ~~or~~ — 7 days

4. 12. 19

telon  
St. Ly





भारत सरकार

Government of India




गिरीश कुमार

Gireesh Kumar

जन्म तिथि/DOB: 01/01/1976

पुरुष/ MALE



मेरा आधार, मेरी पहचान





भारतीय विशिष्ट पहचान प्राधिकरण

Unique Identification Authority of India

**Address:**

S/O: Ramdeen, 29, rasulapur  
Post ghaghau, Mohammadpur  
Bahari, Firozabad,  
Uttar Pradesh - 205141

**पता:**

आत्मज: रामदीन, 29, रसूलपुर पोस्ट घाघऊ,  
मोहम्मदपुर बाहरी, फिरोजाबाद,  
उत्तर प्रदेश - 205141



1947



help@uidai.gov.in



www.uidai.gov.in